Anterior Abdominal Wall & Inguinal Region

Lab 7

October 14, 2026 - Dr. Liu (kenneth.liu@ubc.ca)

Dissector

Objectives:

- Compare the anatomy to it representation in imaging modalities
- Define the conceptual overview of the anterior abdominal wall region
- Describe the anatomical relationship between abdominal muscles, rectus sheath and inguinal canal
- Discuss the contents of the inguinal canal in males and females
- Explain the clinical correlations between the structure of the inguinal canal and different types of inguinal hernias

Resources:

Clinical Anatomy (Web)

Anterior Abdominal Wall (Atlas)

Rectus Muscle & Sheath (Atlas)

Anterolateral Muscles (Atlas)

Anterior Abdominal Wall (Module)

Inguinal Canal (Module)

Abdomen Dissection (Video)

Surface Anatomy:

Be able to describe:

- Subcostal & transtubercular planes, midclavicular line
- Regions of the abdomen used for ease of description (i.e. the anatomical divisions of the abdomen)
- Normal surface location of the appendix
- Dermatomes of the anterior abdominal wall

Be able to identify surface landmarks:

- ◯ Costal margins (fused costal cartilages of ribs VII to X)
- ◯ Xiphoid process of sternum
- ◯ Iliac crest
- ◯ Anterior superior iliac spines (ASIS)
- ◯ Pubic tubercle
- ◯ Inguinal ligament
- ◯ Umbilicus

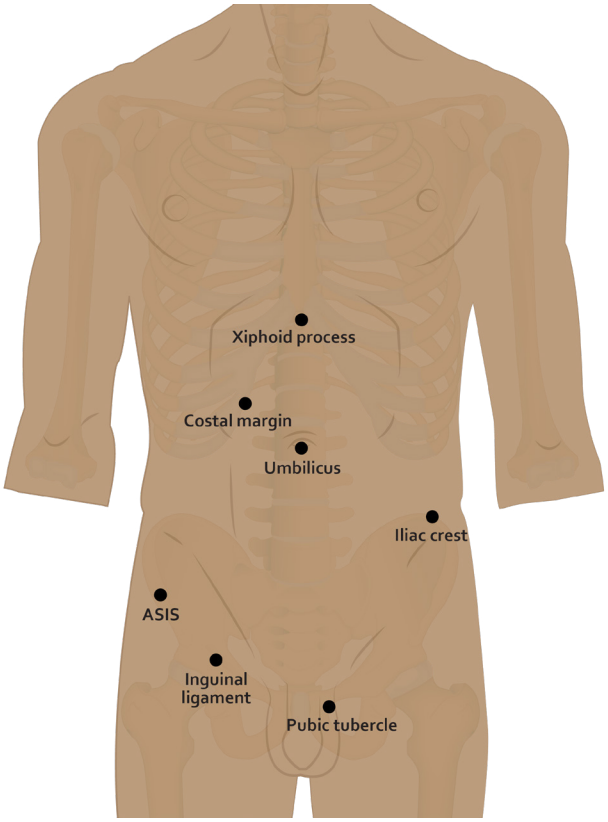

October 14, 2026 - Dr. Liu (kenneth.liu@ubc.ca)

Anterior Abdominal Wall:

Be able to describe:

- Cutaneous innervation of the anterior abdominal wall
- Innervation of anterior abdominal musculature
- Functional roles of the anterior abdominal musculature
- Define hernias and know:
  - Positions of deep and superficial inguinal rings
  - Direct and indirect hernias
  - Other common sites of hernias involving the abdominal contents

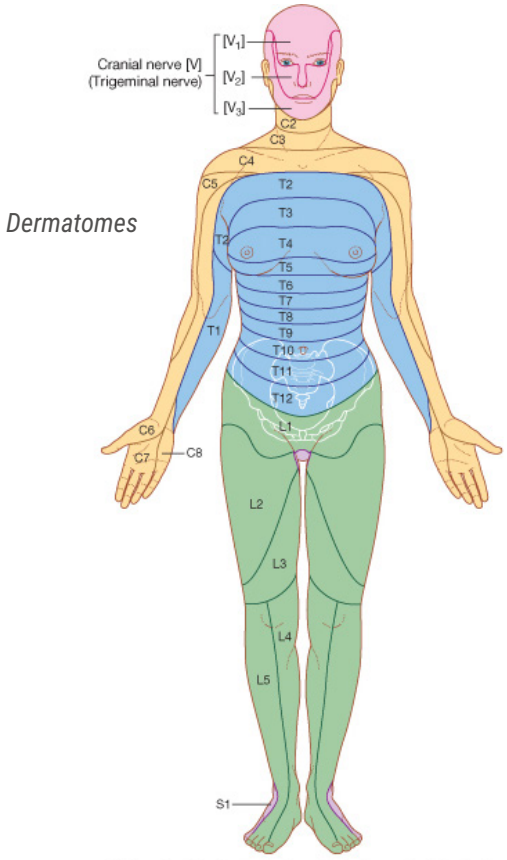

© Elsevier. Drake et al: Gray's Anatomy for Students
www.studentconsult.com

Hide Labels

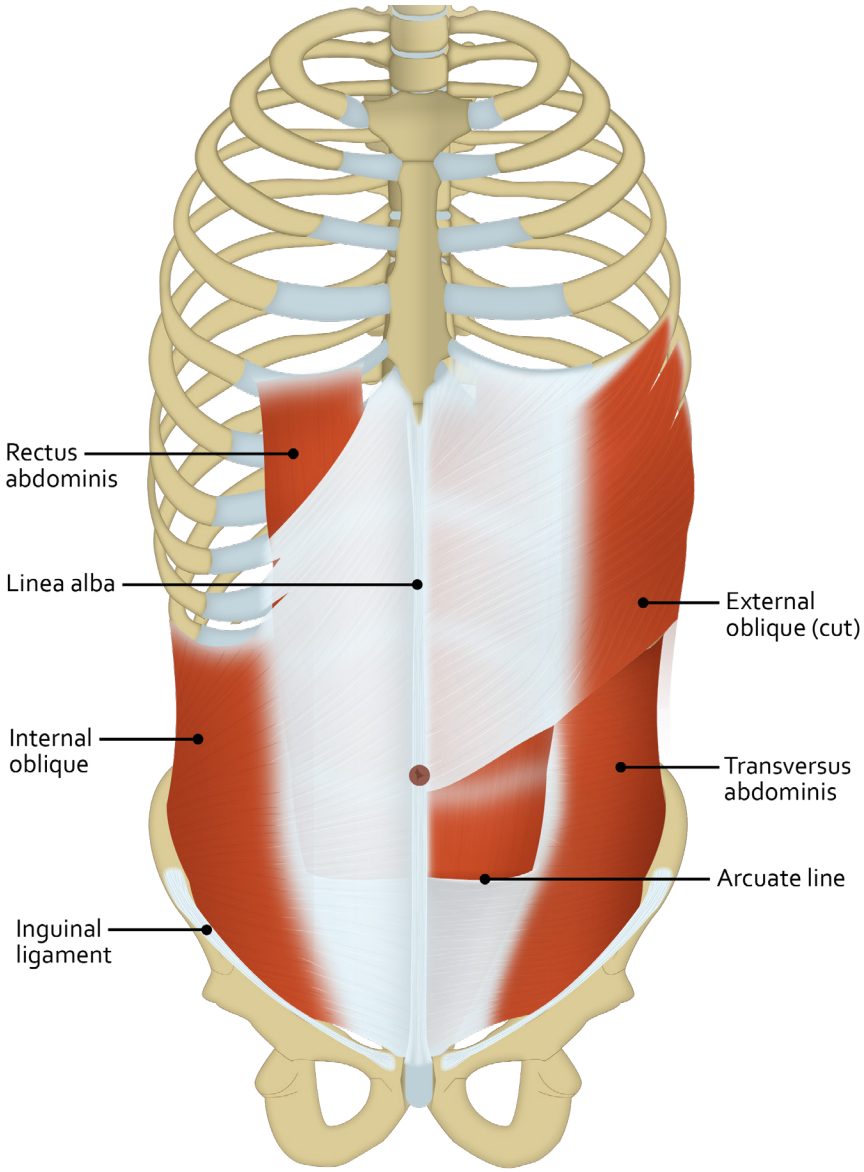

Be able to identify:

- ◯ Peritoneum
  - Parietal and visceral
- ◯ Fascia
  - Rectus sheath
  - Transversalis fascia
- ◯ Muscles
  - External oblique
  - Internal oblique
  - Transversus abdominis
  - Rectus abdominis
- ◯ Inguinal region
  - Inguinal ligament
  - Superficial inguinal ring
  - Inguinal canal and its contents (male & female)
  - Conjoint tendon
  - Position of deep inguinal ring
- ◯ Arteries
  - Superior epigastric
  - Inferior epigastric

October 14, 2026 - Dr. Liu (kenneth.liu@ubc.ca)

Muscle Layers - Rectus Abdominis:

- ◯ Rectus sheath
  - anterior layer
  - posterior layer
- ◯ Tendinous intersections
- ◯ Arcuate line
- ◯ Linea alba
- ◯ Inferior epigastric artery
- ◯ Superior epigastric artery

Cross-Section of Rectus Sheath

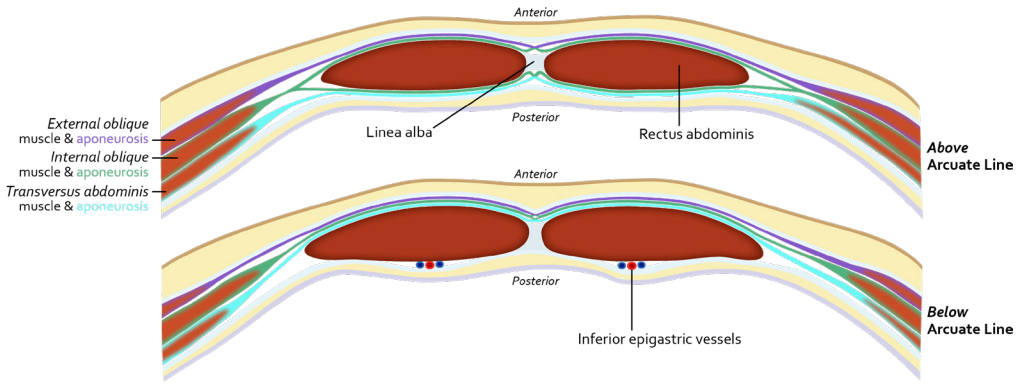

Hide Labels

Dissection of Rectus Abdominis Muscle

October 14, 2026 - Dr. Liu (kenneth.liu@ubc.ca)

Hide Labels

Rectus Sheath and Vessels

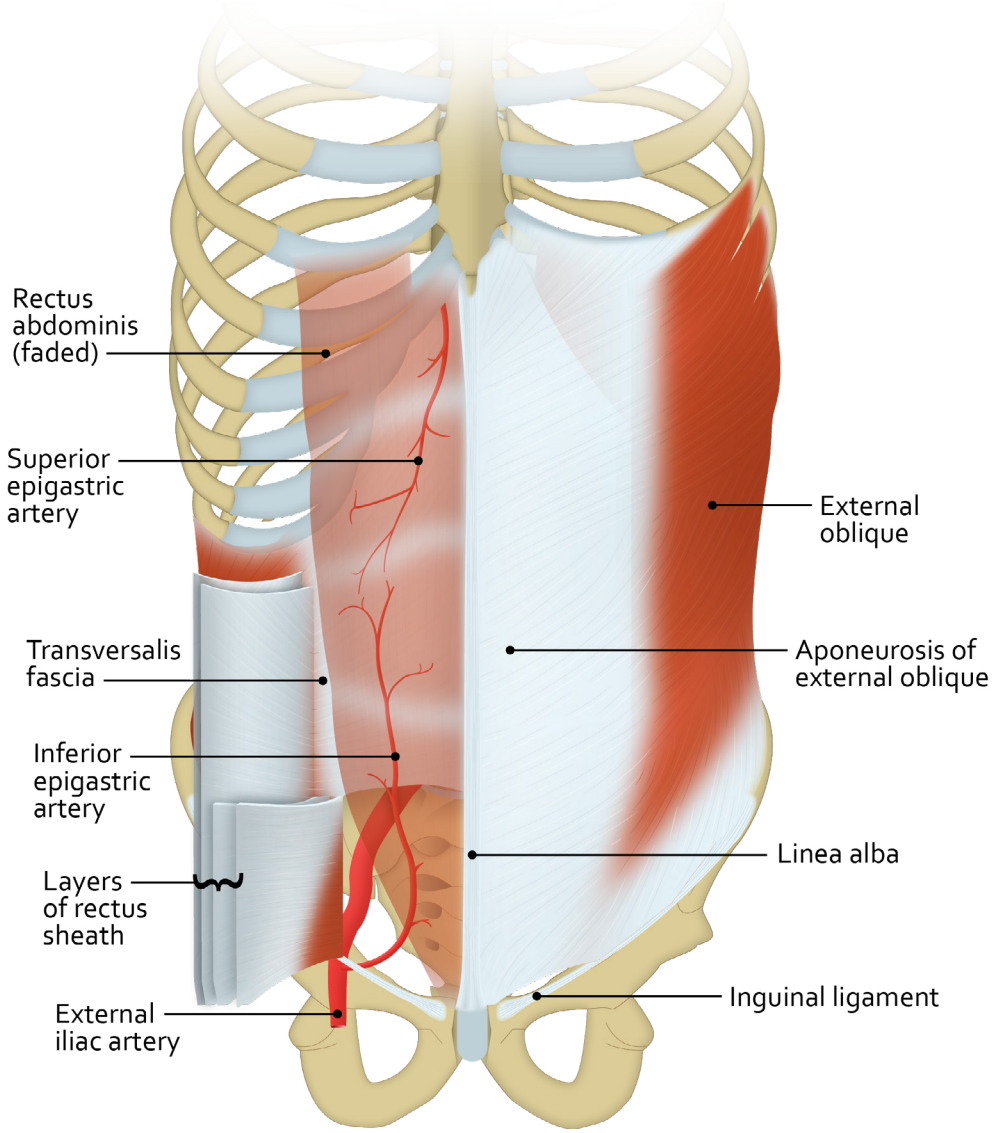

Muscle Layers - External & Internal Oblique, Transversus Abdominis:

- ◯ External oblique
- ◯ External oblique aponeurosis (part of anterior layer of rectus sheath)
- ◯ Superficial inguinal ring
- ◯ Inguinal ligament
- ◯ Spermatic cord
- ◯ Internal oblique
- ◯ Transversus abdominis

October 14, 2026 - Dr. Liu (kenneth.liu@ubc.ca)

Hide Labels

External Obliques

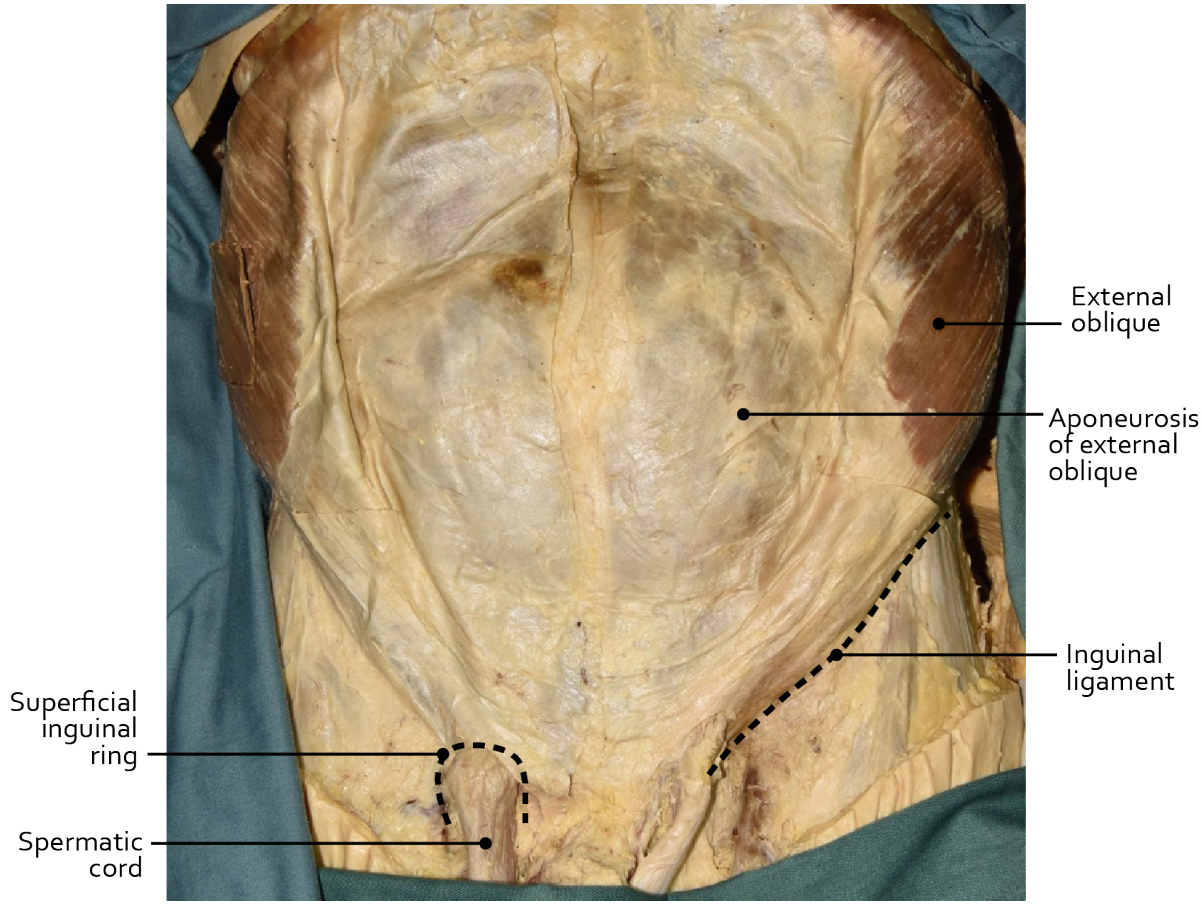

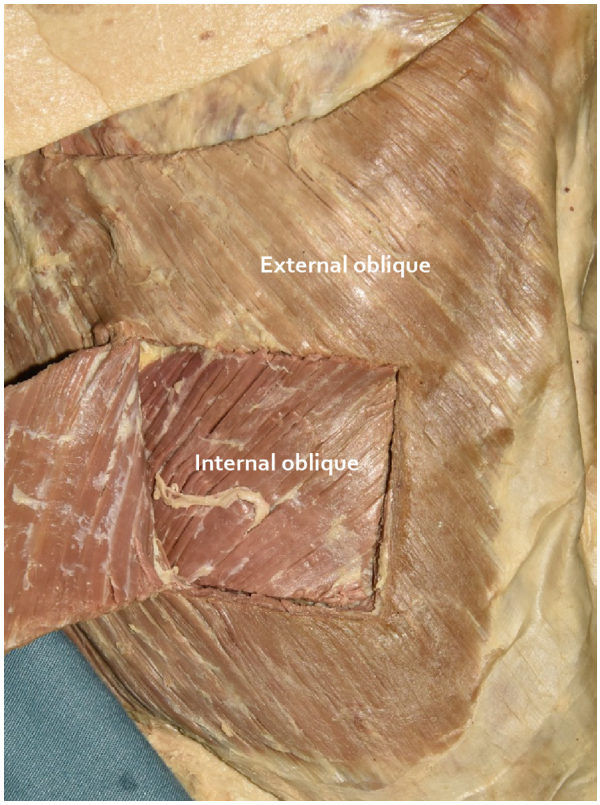

Right Abdominal Wall

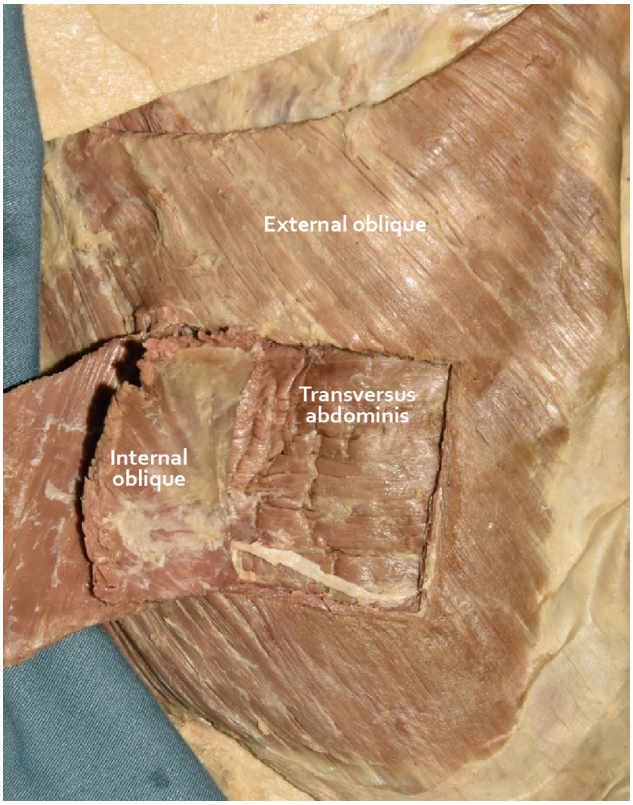

October 14, 2026 - Dr. Liu (kenneth.liu@ubc.ca)

Inguinal Region:

- ◯ Inguinal ligament
- ◯ Superficial inguinal ring
- ◯ Inguinal canal and its contents
- ◯ Conjoint tendon
- ◯ Position of deep inguinal ring
- ◯ Spermatic cord

In the Male:

- ◯ Identify the spermatic cord in relation to the inguinal rings and inguinal canal

In the Female:

- ◯ Identify the round ligament of the uterus as it exits the superficial inguinal ring
  - Understand that the female has an inguinal canal and that it contains, as does the male, remnants of the processus vaginalis

Inguinal Canal (Module)

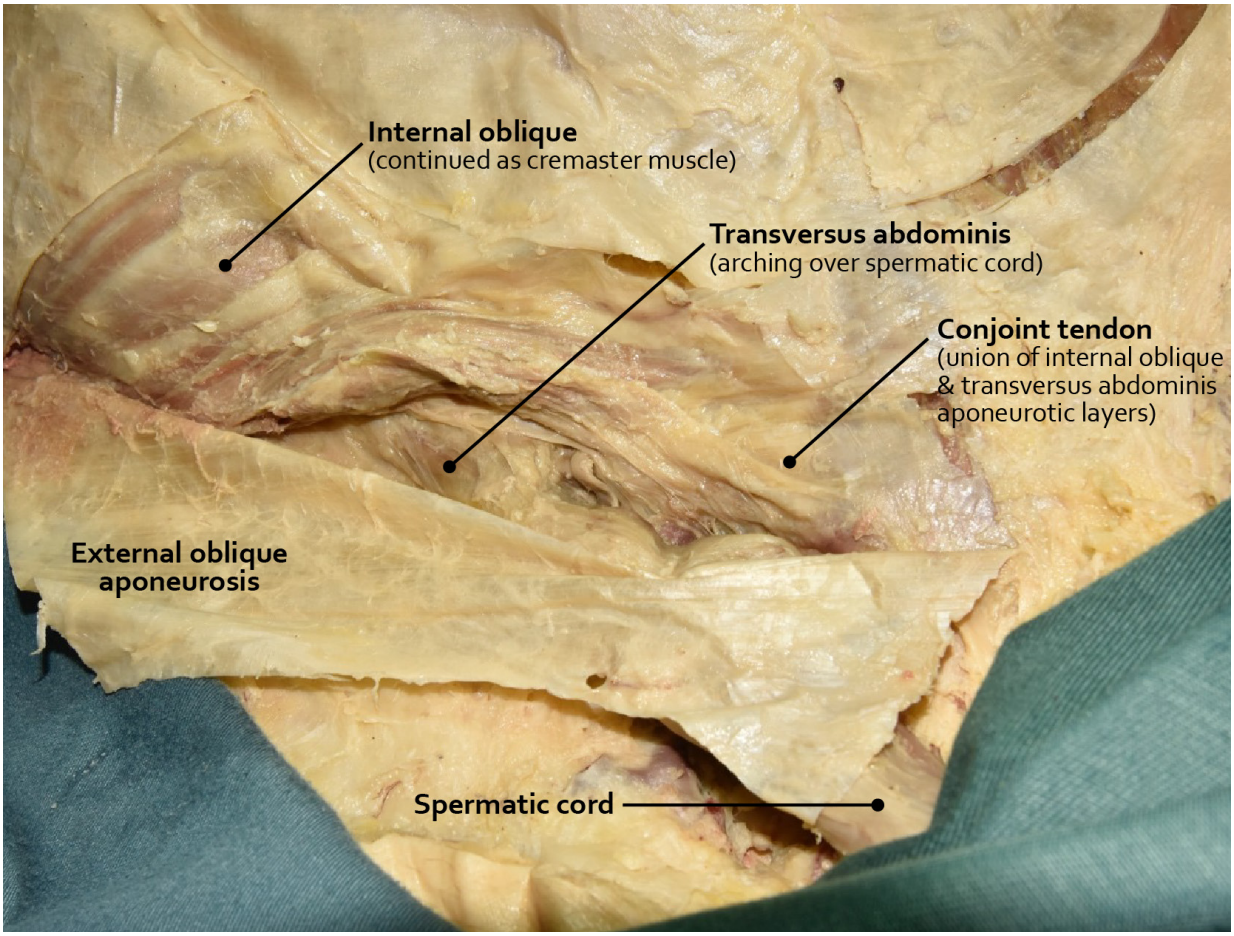

Right Inguinal Region

Separating the Anterior Abdominal Wall Muscles

1. *Palpate the anterior superior iliac spine (ASIS) and pubic symphysis and appreciate the border between the abdomen and the thigh.*
2. *Make a skin incision down the midline, and along a line between the pubic symphysis and the anterior superior iliac spine. You can make an additional incision from the umbilicus to the side. Reflect the superficial fascia (see figure below).*
3. *Reflect the anterior abdominal wall skin with the thick superficial and deep fascia laterally (all together at once). As long as you can see the external abdominal muscle and its aponeurosis on both sides of the midline, you are in the correct plane (level).*

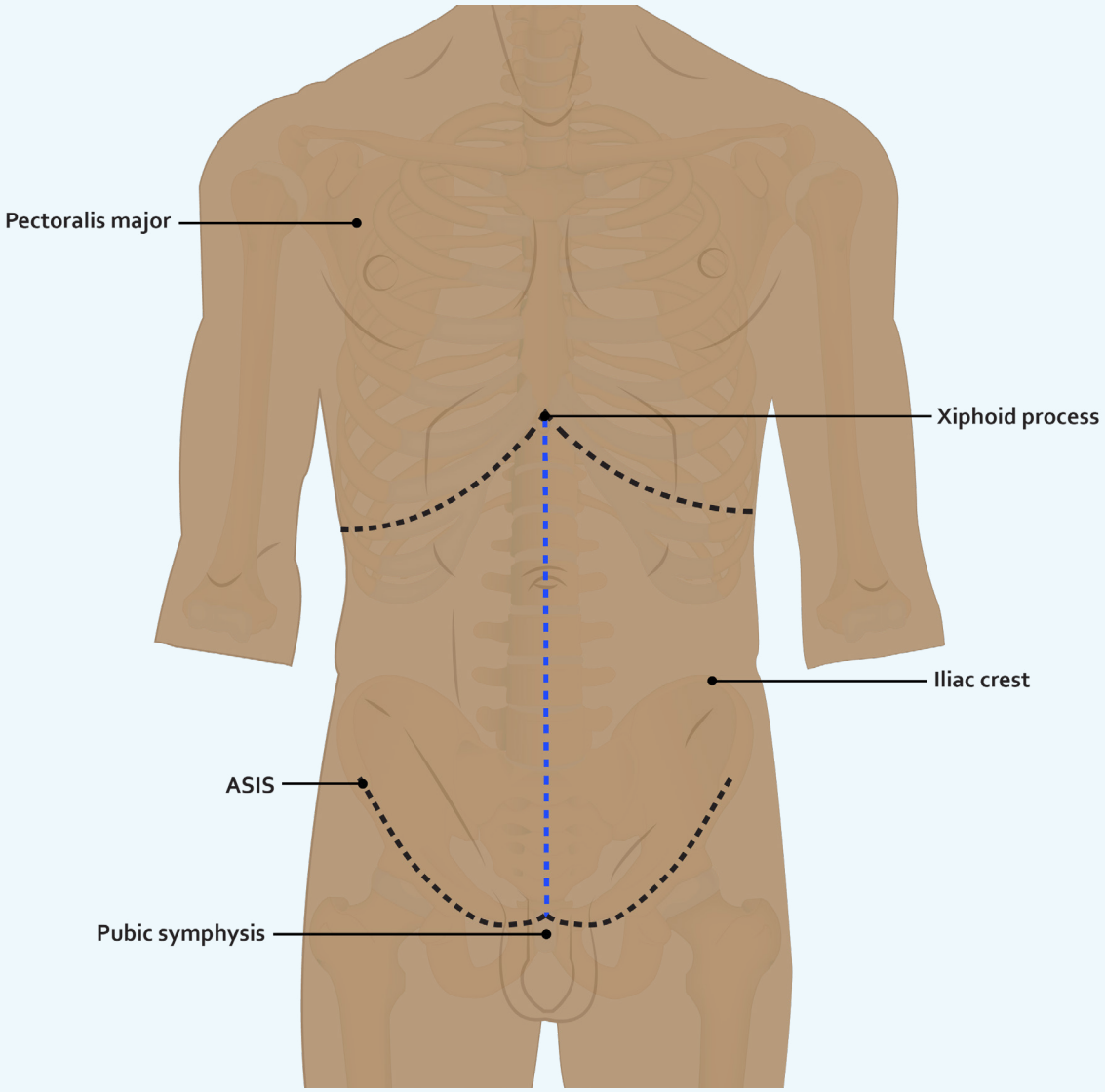

Separating the anterior abdominal wall muscles (step 2)

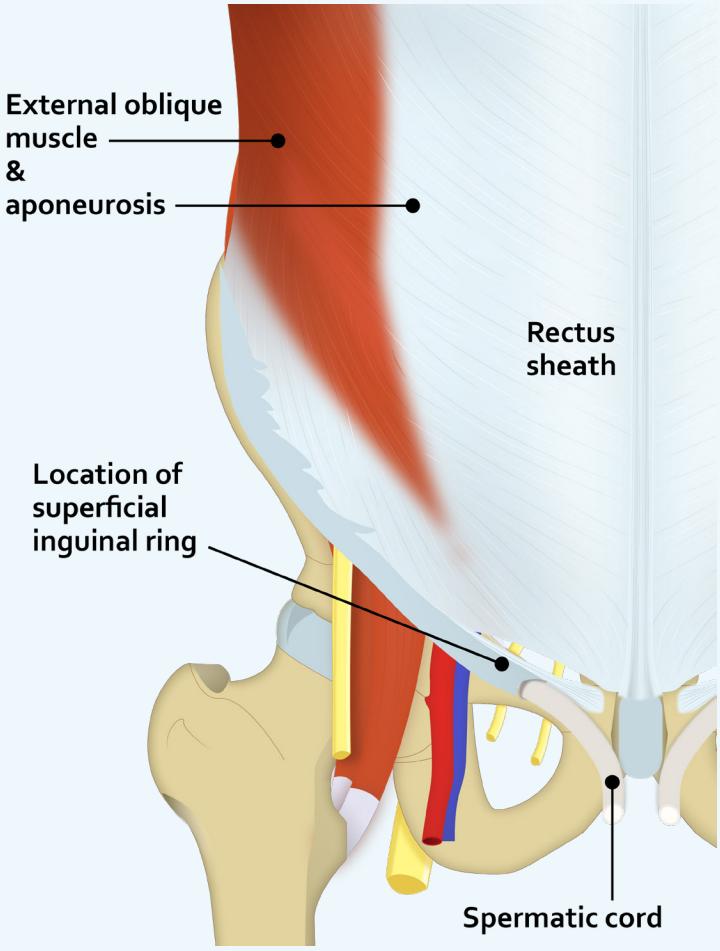

1. *Examine the superficial inguinal ring, its crura, and spermatic cord or round ligament of uterus and ilioinguinal nerve coming out from it. You can use these anatomical structures as the landmarks to explore the margins of the ring. You also should examine the inguinal ligament and appreciate that it is the inferior free border of the external oblique aponeurosis.*

2. *Make a vertical incision in the lumbar (flank) region from 3-4 cm posterior to the anterior superior iliac spine (ASIS) all the way up to the origin of the external oblique muscle (where it is interdigitated with the serratus anterior muscle).*

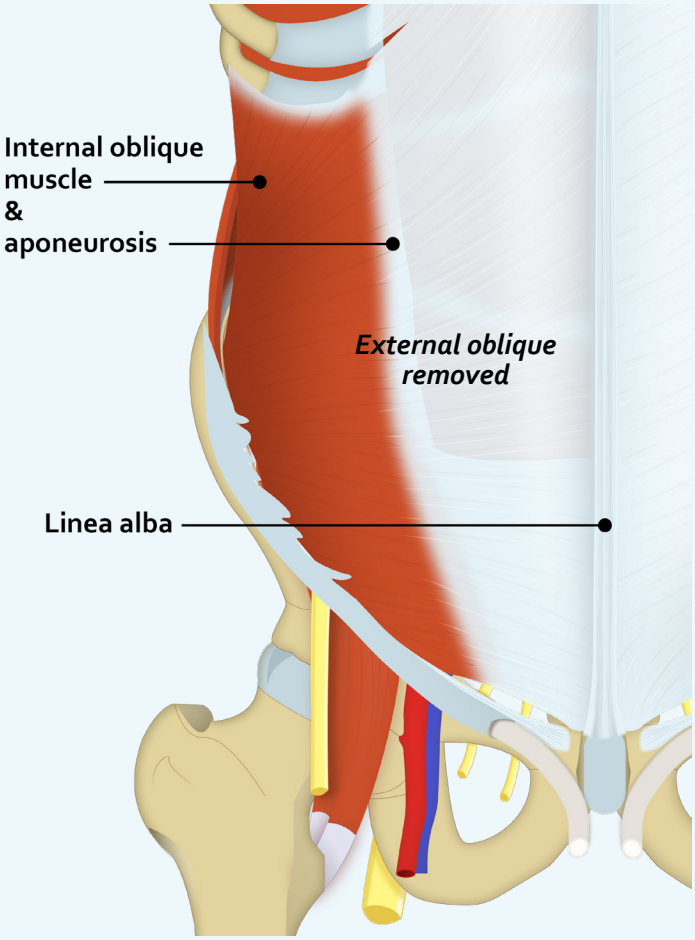

3. *Separate the fibers of the external oblique from the internal oblique muscle along the incision line, and reflect the divided external oblique anteriorly and posteriorly to expose the underlying internal oblique muscle. Notice that its fibers take a different direction than the external oblique muscle.*

4. *Incise the internal oblique muscle at the same place and separate it from the transversus abdominis muscle by reflecting it anteriorly and posteriorly.*

Inguinal Canal Dissection

1. *Make a shallow transverse incision in the aponeurosis of the external oblique muscle from ASIS to the lateral border of the rectus sheath. Make an oblique incision from the end point of the previous incision to the pubic tubercle.*

   ***** This incision MUST end medially to the superficial inguinal ring *****

   (do not disturb the superficial inguinal ring as you need it later for review)

2. *Reflect the inferior part of the divided external oblique aponeurosis inferiorly. You have now opened the inguinal canal. Examine the spermatic cord or round ligament of uterus and ilioinguinal nerve as the contents of the canal. You can also examine the inferior border of the internal oblique muscle as it passes over the spermatic cord (or round ligament of uterus).*

3. *The conjoint tendon is behind the superficial inguinal ring. Examine it and appreciate that it is formed by the fusion of the aponeuroses of the internal oblique and transversus abdominis muscles.*

4. *The next step is to reflect the internal oblique muscle and expose the deep inguinal ring; however in most cases even the fleshy parts of these two muscles are fused to each other at this point.*

5. *Find the ilioinguinal nerve in the inguinal canal and use it as a guide to separate the internal oblique muscle from transversus abdominis, as this nerve passes between these two muscles. Split the internal oblique muscle along the course of its fibers where it is pierced by the ilioinguinal nerve. Pass your scissors (or probe) between the two muscles and after separating the muscles, cut the internal oblique to its inferior border, and reflect the divided internal oblique laterally and medially. You should be able to see the inferior border of the transversus abdominis passing over the spermatic cord or round ligament of the uterus. This is the deep inguinal ring.*

6. *Clean the deep inguinal ring and find the inferior epigastric vessels shining through the transversalis fascia and located medially to the deep ring.*

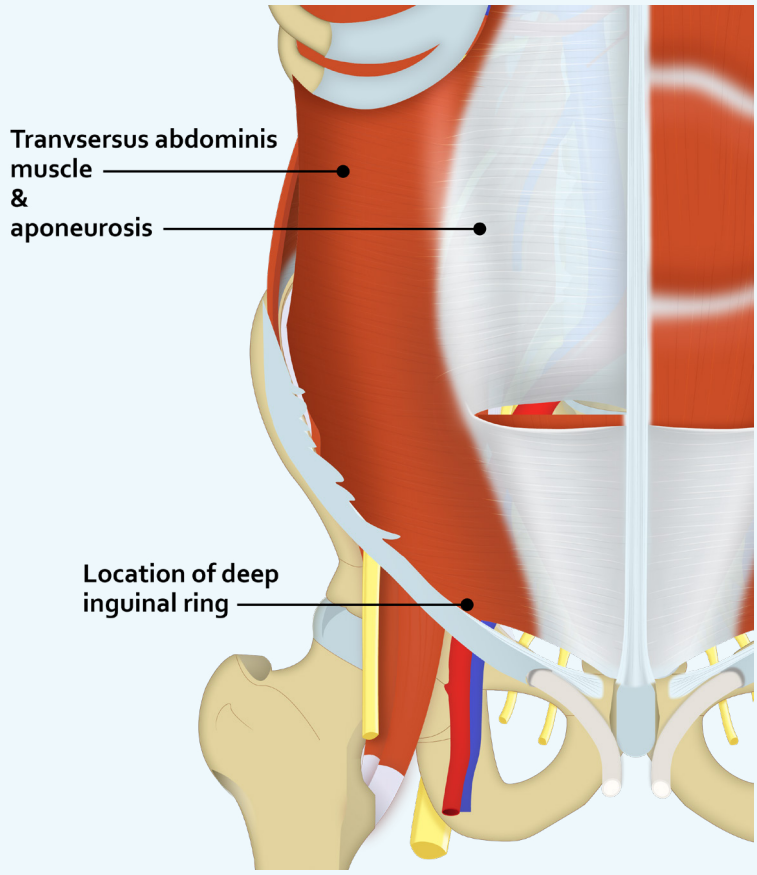

External oblique, internal oblique and rectus abdominis removed

Rectus Sheath Dissection

1. *Make a shallow vertical incision along the midpoint of the anterior surface of the rectus sheath **(do it only on one side)**. Inferior to the umbilicus the incision should be closer to the midline, and superior to the umbilicus it should be farther from midline.*
2. *Reflect the anterior wall of the sheath and expose the rectus abdominis muscle.*
3. *Divide the rectus abdominis in its middle and reflect its two halves superiorly and inferiorly. You should be able to easily find the inferior epigastric vessels inside the sheath now.*
4. *Examine the posterior wall of the rectus sheath and find the arcuate line.*

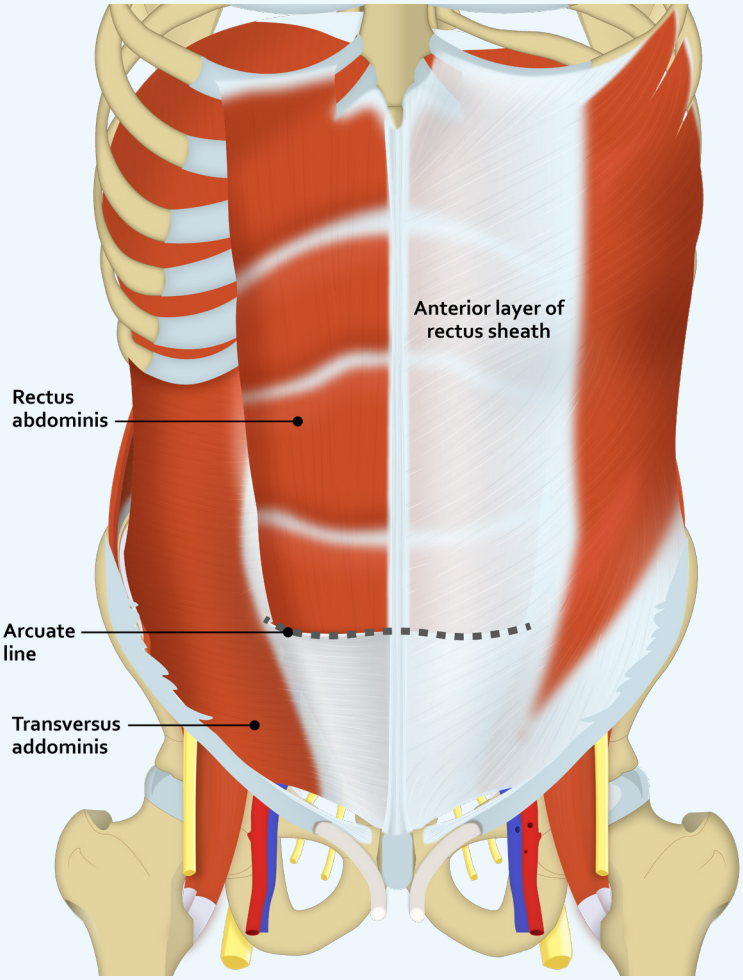

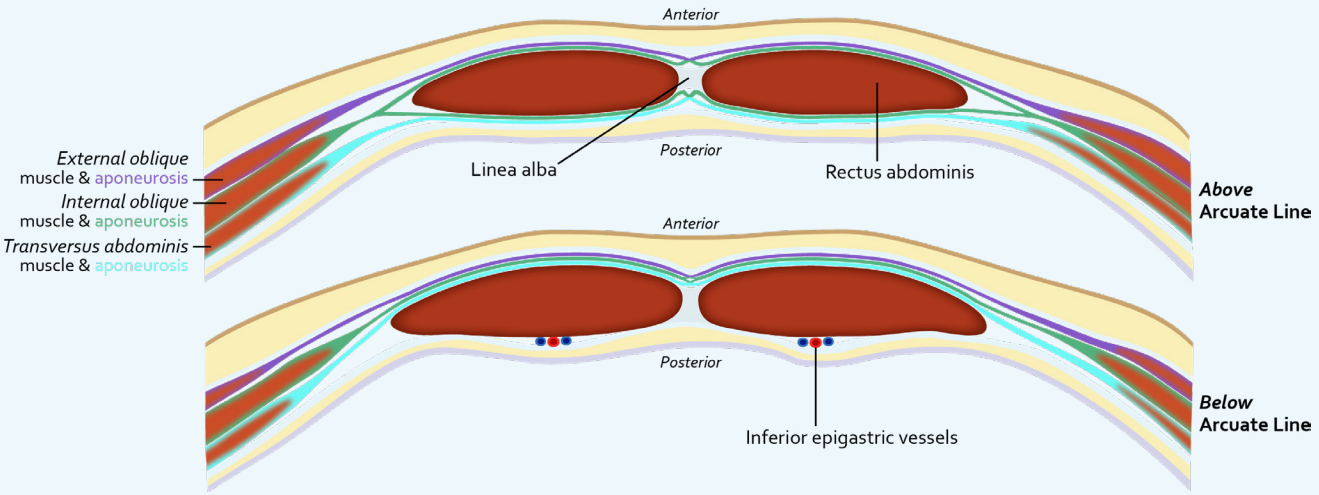

Cross-section of rectus sheath