Midgut & Hindgut Organs and Vessels

Lab 9

November 10, 2026 - Dr. Doroudi (*majid.doroudi@ubc.ca*)

Dissector

Objectives:

- Describe the derivatives of the midgut and hindgut organs
- Identify and define the superior and inferior mesenteric arteries and demonstrate the blood supply of the midgut and hindgut organs
- Identify the different parts of the large intestine
- Describe the the venous drainage of the midgut and hindgut
- Identify and define the blood supply of the organs derived from hindgut
- Describe the sympathetic and parasympathetic input to the prevertebral plexus and the route the fibers take to the viscera

Watch this dissection guide video:

Midgut Dissection (Video)

View the interactive modules:

Midgut (Module) Hindgut (Module)

Identify checklist structures on the interactive photo and specimens in the virtual lab:

Midgut (Atlas) Mesentery (3D) Abdominal Cavity (3D)

Viscera:

- ◯ Small intestine
  - Jejunum
  - Ileum
  - Ileocecal junction and valve
  - Identify jejunum versus ileum

Small Intestine in Situ
(B. Kathleen Alsup & Glenn M. Fox, University of Michigan Medical School, BlueLink)

November 10, 2026 - Dr. Doroudi (majid.doroudi@ubc.ca)

Comparison of ileum and jejunum dissections

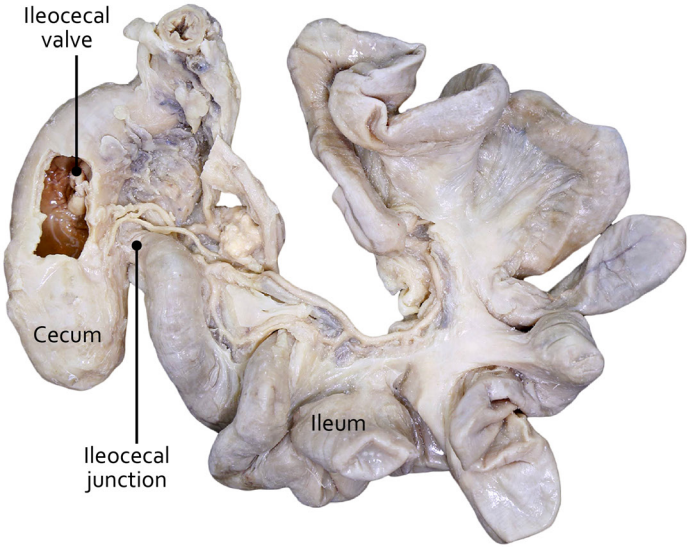

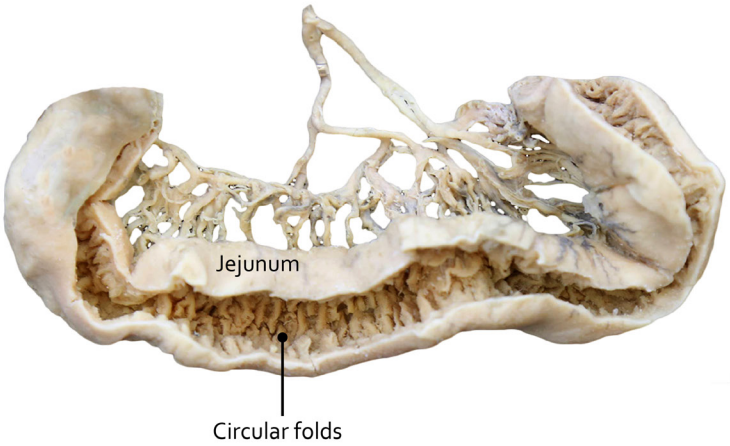

Main features of ileum: thinner wall, no circular folds, many Peyer's patches

November 10, 2026 - Dr. Doroudi (majid.doroudi@ubc.ca)

Viscera:

- Large intestine
  - Appendix
  - Ascending, transverse, descending, sigmoid portions of colon
  - Rectum and anal canal (will be examined with pelvis)
  - Taeniae coli, haustra coli, epiploic (omental) coli

What is the significance of the left colic flexure with respect to parasympathetic innervation?

Answer

Hide Labels

Large Intestine in Situ
(B. Kathleen Alsup & Glenn M. Fox, University of Michigan Medical School, BlueLink)

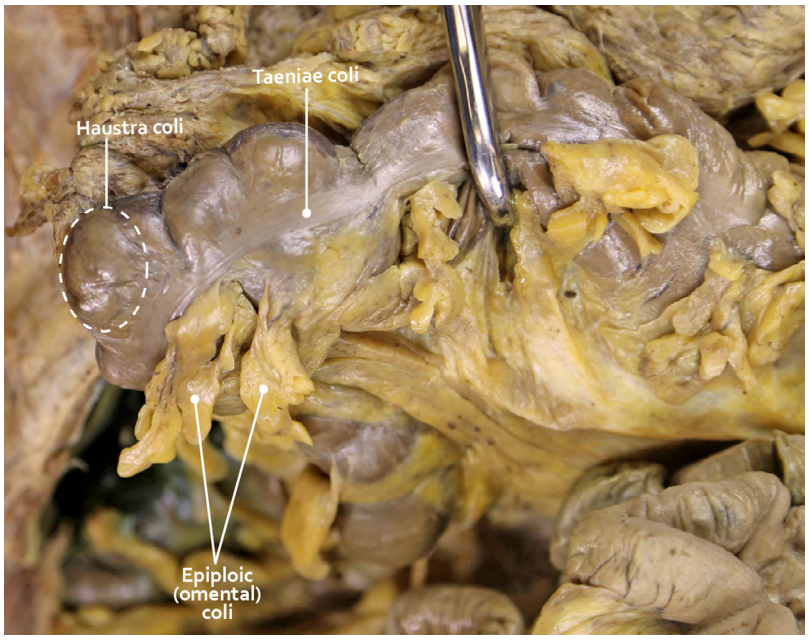

Hide Labels

Components of Colon
(B. Kathleen Alsup & Glenn M. Fox, University of Michigan Medical School, BlueLink)

November 10, 2026 - Dr. Doroudi (majid.doroudi@ubc.ca)

Arteries:

- Superior mesenteric
- Inferior mesenteric

Hide Labels

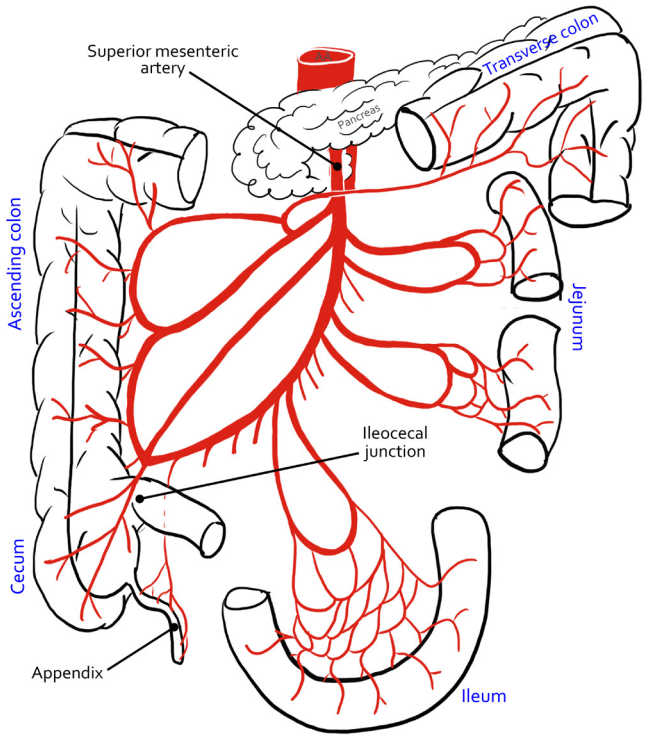

Superior mesenteric artery supplies the midgut

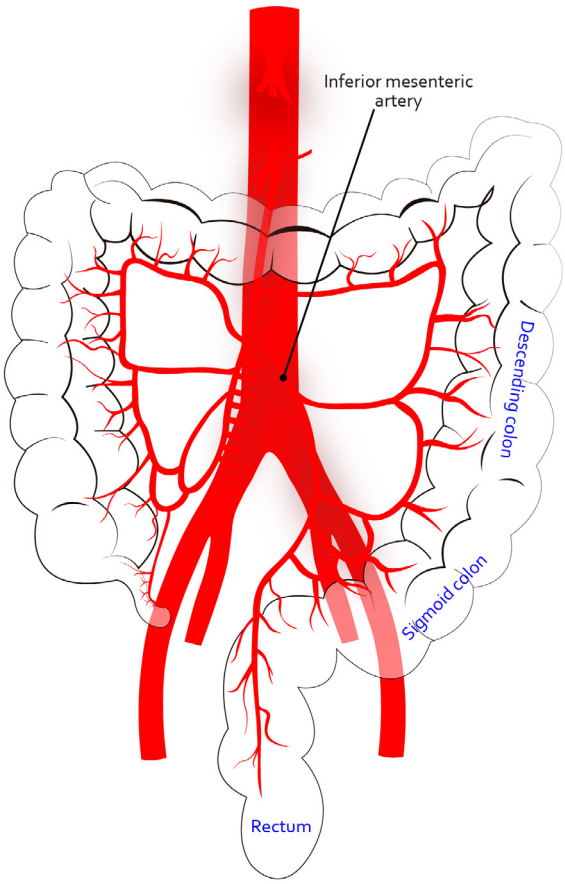

Inferior mesenteric artery supplies the hindgut

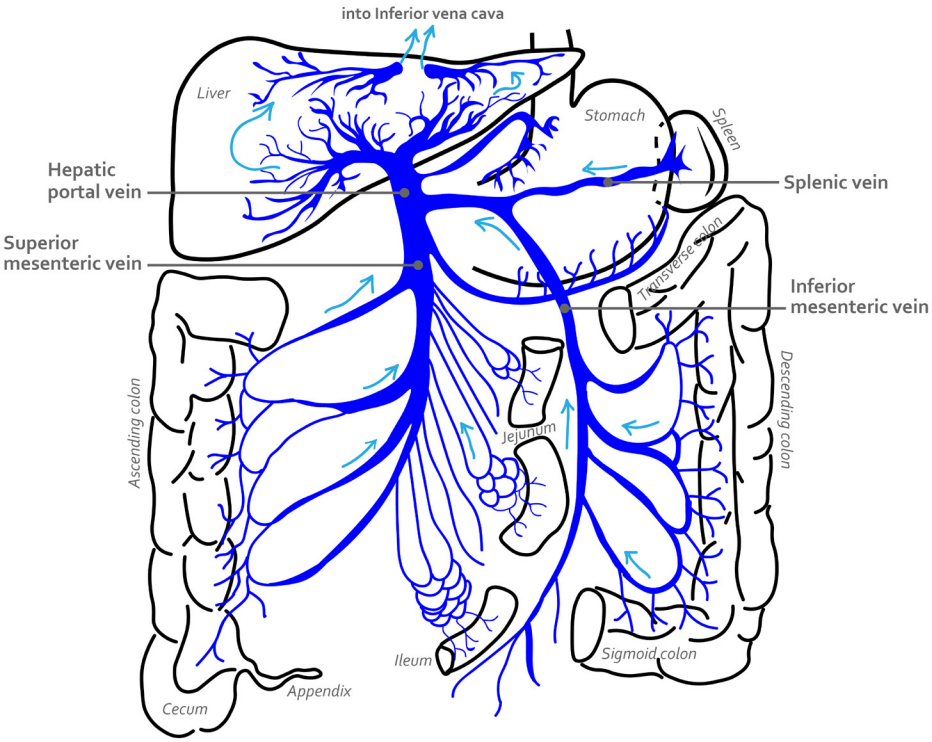

Veins:

- Superior mesenteric
- Inferior mesenteric
- Splenic
- Portal veins to liver

Hide Labels

Venous drainage of the midgut and hindgut

November 10, 2026 - Dr. Doroudi (*majid.doroudi@ubc.ca*)

Hide Labels

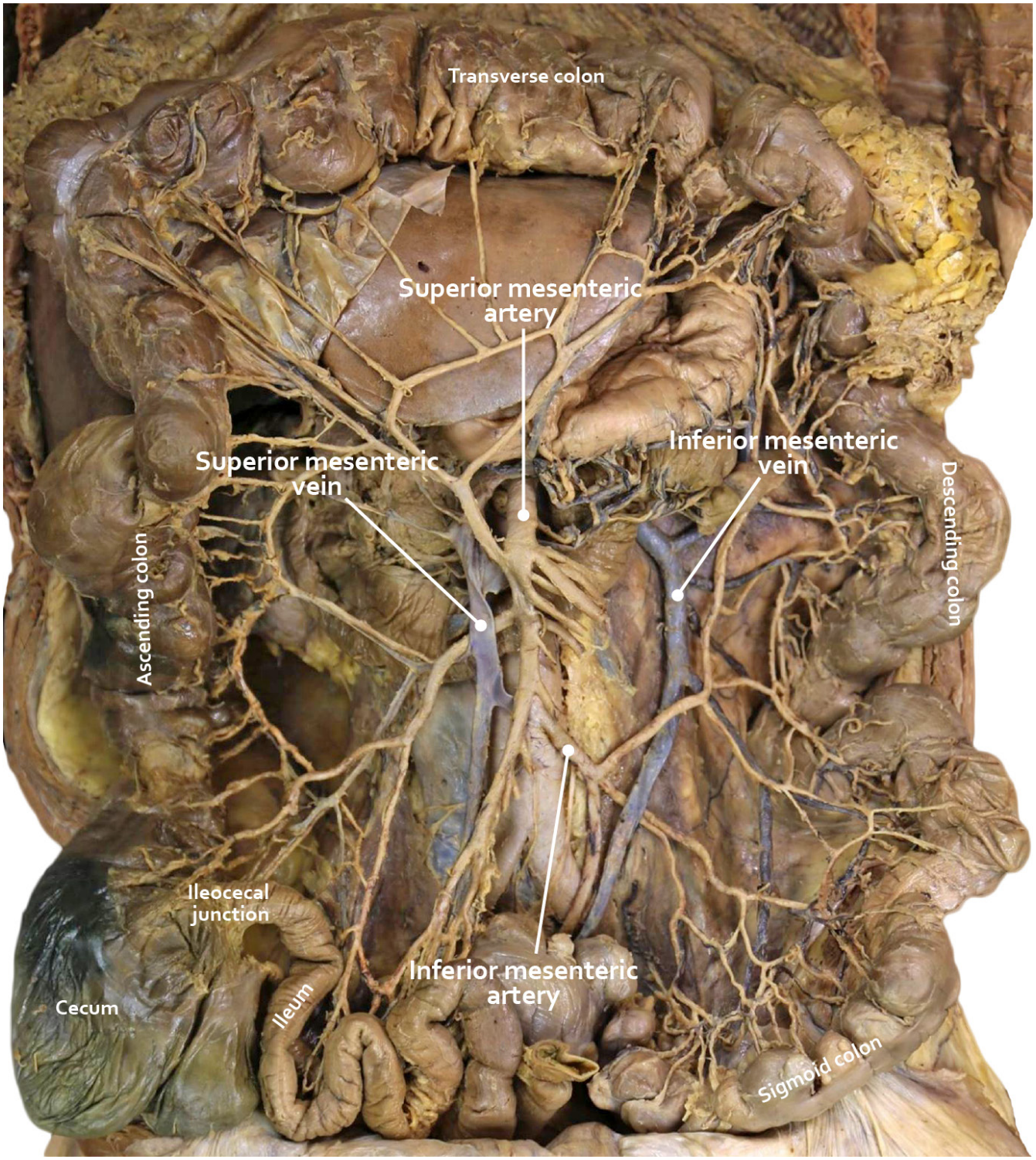

Vessels of the Midgut and Hindgut
(B. Kathleen Alsup & Glenn M. Fox, University of Michigan Medical School, BlueLink)

November 10, 2026 - Dr. Doroudi (majid.doroudi@ubc.ca)

Midgut Innervation:

- Superior mesenteric ganglion near root of superior mesenteric artery
- **Sympathetic** nervous system: **T5-T12** (lesser splanchnic nerve)
- **Parasympathetic** nervous system: **vagus nerve**

- Distribution of postganglionic (sympathetic) or preganglionic (parasympathetic) nerve fibers is via arteries
- **Sympathetics:** inhibitory to gut muscles (and visceral sensory nerves that transmit pain travel with them to enter the spinal cord)
- **Parasympathetics:** motor to gut muscles
- **Visceral Sensory:** pain fibers travel with sympathetic fibers

Hindgut Innervation:

- Inferior mesenteric ganglion near root of inferior mesenteric artery
- **Sympathetic** nervous system: **L1 & L2**
- **Parasympathetic** nervous system: **S2 - S4**

November 10, 2026 - Dr. Doroudi (majid.doroudi@ubc.ca)

Midgut Dissection (Video)

Exploring the Midgut and Hindgut Organs

1. *Spread the greater omentum hanging from the greater curvature of the stomach and then reflect it superiorly.*
2. *Find the attachment of the transverse mesocolon to the posterior abdominal wall and from this point try to put the large intestine in the anatomical position. It will frame the small intestine (jejunum and ileum):*
   - You should be able to find the cecum, appendix, ascending colon, right colic flexure, transverse colon, left colic flexure, descending colon, sigmoid colon and rectum

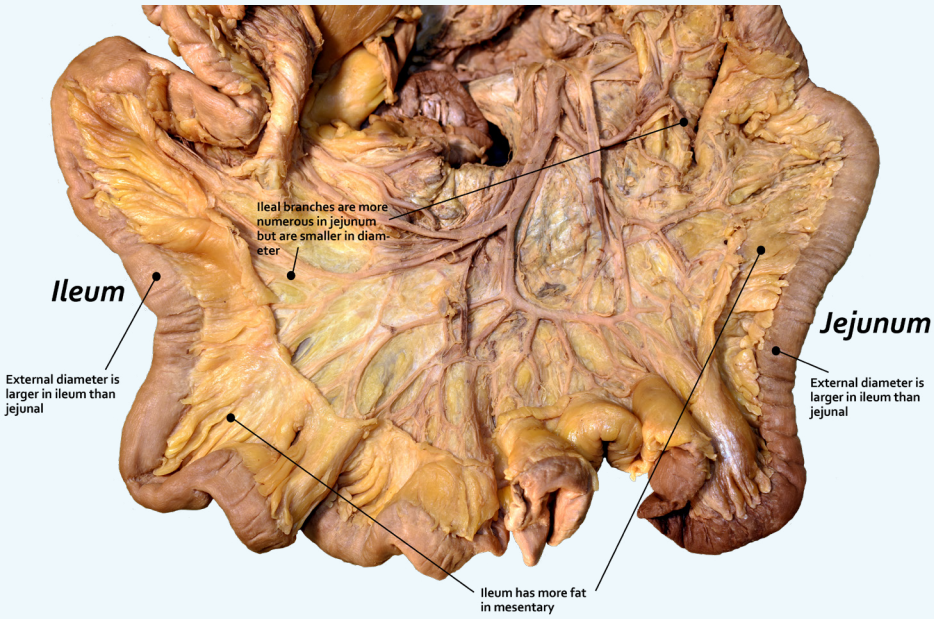

3. *Find one of the colon's taenia coli (ascending, transverse, descending colon) - **usually the easist to find is on the anterior surface of ascending colon or on transverse colon**.*
4. *Appreciate the formation of the haustra coli due to the fact that the teniae coli are shorter than the real length of the colon. Identify the taenia coli and the haustra coli.*
5. *Find epiploic (omental) appendices on the surface of the colon **(substantial numbers on sigmoid colon)**.*

Superior Mesenteric Artery (SMA)

1. *Since the mesentery is a double layered peritoneal fold and ALL the branches of SMA are passing between its two layers, we only need to remove one layer of the mesentery in order to expose the arteries.*
2. *Put the small and large intestines in the anatomical position and pull the jejunum and ileum to the left side of the abdominal cavity:*
   - You should now be able to see the mesentery of the jejunum and ileum attaching to the posterior abdominal wall
3. *Remove only one layer of the mesentery close to the beginning of the jejunum and find the stem of the superior mesentery artery (and accompanying vein on its right side).*
4. *During the dissection of SMA, appreciate that there is substantial number of nerve fibers accompanying the arteries, forming the superior mesenteric nerve plexus:*
   - You also should be able to find many lymphatic nodules between the two layers of the mesentery (not easy to distinguish from fat)

Note: You do not need to dissect the branches of SMA - we will do it in the midgut / hindgut lab in MEDD 422

Inferior Mesenteric Artery (IMA)

1. *Pull the jejunum and ileum loops to the right side of the abdominal cavity and expose the posterior abdominal wall between the mesentery, transverse mesocolon and descending colon.*
2. *Find the stem of IMA behind the parietal peritoneum.*
3. *Like the SMA and its branches, the IMA and its branches are surrounded by substantial number of nerve fibers, forming the inferior mesenteric nerve plexus.*

> **Note:** You do not need to dissect the branches of IMA - we will do it in the midgut / hindgut lab in MEDD 422

Portal Vein and its Tributaries

1. *Trace the **inferior mesenteric vein** on the left side of IMA superiorly to the inferior border of the pancreas.*
   - It will drain into the **splenic vein** at this point. (With a high percentage of normal variation, sometimes in drains into the superior mesenteric vein or even directly to the portal vein)
2. *Follow the **splenic** vein to the right and appreciate that it joins to the superior mesenteric vein behind the neck of pancreas and forms the portal vein.*
3. ***Portal vein** will move superiorly through the hepatoduodenal ligament and drains into the liver by passing through porta hepatis.*

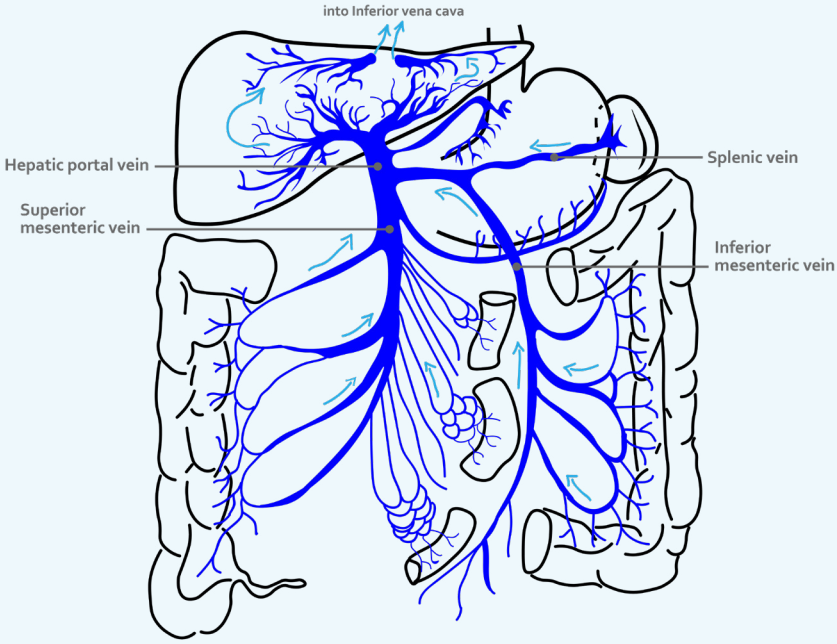

Opening the Midgut and Hindgut Organs

1. *If the jejunum and ileum as well as the cecum are almost empty, we suggest you to do the next step of the midgut and hindgut dissection.*
2. *Close to the duodenojejunal junction, tie the two ends of a 3cm long of jejunal loop with string.*
3. *Open the wall of the jejunum like a window and clean inside the lumen of the loop by paper towel.*
4. *Do the same procedure for a loop of ileum and compare the mucosal layer of these two regions of the small intestine:*
   - You may be able to see the Peyers' patches under the mucous membrane of the ileum
5. *Ligate (tie) the ascending colon 2cm superior to the ileocecal junction:*
   - Open a window at the anterior wall of the cecum at the level of the ileocecal junction. Put the hinge of the window close to the ileocecal junction
6. *Clean inside the cecum with paper towel and try to find the ileocecal valve.*